

CASE STUDY: STALLED DIABETIC LEG ULCER LOCATED ON THE LATERAL MALLEOLAR OF LEFT LEG



BACKGROUND

A 56 year old male patient with a diabetic ulcer located on the lateral malleolus on the left leg. The patient also suffered from arterial/venous failure, but had otherwise good nutritional status and normal mobility. The ulcer was defined as a stalled wound, more than 5 months old, and was first diagnosed on 26th August 2015. Measurements were 4,5 cm². Several efforts had been implemented to heal or at least improve the wound. This included treatments with gels, alginates, collagen and hyaluronic acid.

CLINICAL ASSESSMENT AND TREATMENT

First consultation 26th August 2015.
Dry wound with no exudate or malodour.
The skin surrounding the ulcer had some redness, but was otherwise intact. The patient received antibiotics. Several different treatments had been instigated earlier with no improvement, hence it was decided to try Woulgan. During the treatment period, traditional wound cleansing agents were used, in addition was a soft mechanical debridement method performed when needed. Woulgan was applied at each dressing change, normally every 2-3 days. An adhesive foam dressing was used to cover Woulgan. Some protective off-loading and compression stockings were also applied.

At presentation - 26th August 2015
(Figure 1)

To reactivate this hard to heal ulcer, it was decided to start Woulgan treatment.

After 7 months - 16th March 2016
(Figure 2)

- Complete healing observed
- The surrounding skin is healthy and intact, but somewhat fragile which needs additional protection by off-loading

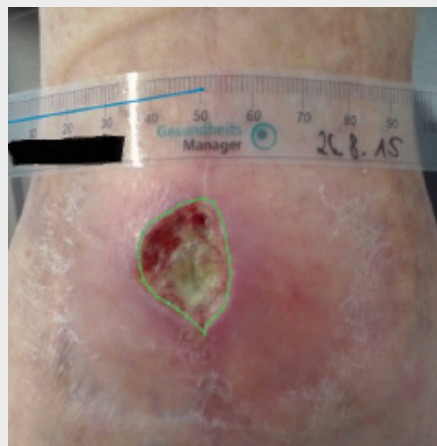

Figure 1: Wound at presentation

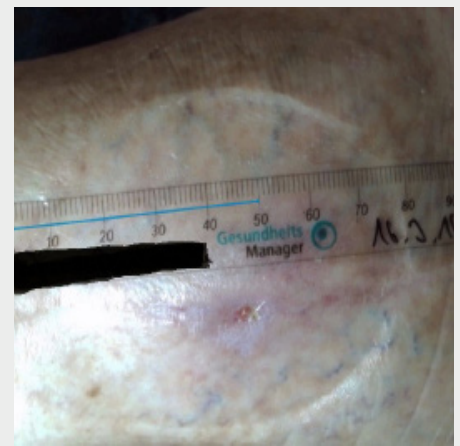


Figure 2: 16 March 2016 - the wound is healed

RESULTS AND DISCUSSION

- Good healing progression and steady reduction of wound size
- Complicating factors that influence the healing process were present

VAS Scale

- 2,5 during dressing changes and 2 during movement for the first 5 months
- Scores decreased to 0,5 in the last 1,5 months of treatment

Other:

- No pain relief treatment needed and no aggravating maceration of the surrounding skin was observed during treatment
- Both patient and clinician were satisfied with the results
- Simple to apply and easy to use
- No safety issues reported
- Woulgan treatment resulted in reactivation of the healing process and complete healing of a severely stalled wound