

CASE STUDY:

14 WEEKS OLD FOOT ULCER CAUSED BY TRAUMA, ON PATIENT WITH VENOUS INSUFFICIENCY



BACKGROUND

Clinical assessment of patient-related factors indicated a 14 weeks old, stalled ulcer and the clinic decided to implement Woulgan after having used standard of care for 3,5 months. 80 years old male with an ulcer located on the dorsum of his foot. The wound developed after a trauma. The patient is also suffering from venous insufficiency which makes it even harder for the wound to heal.

CLINICAL ASSESSMENT AND TREATMENT

The patient suffers from venous insufficiency and suffered an ulcer on the dorsum of his foot. The ulcer has been present for more than 3 months when Woulgan was applied for the first time. Before, Prontosan, zinc paste (around the wound edges), and foam dressings had been used to heal the wound. It has also been debrided.

At presentation - 17th September 2015

(Figure 1)

Leg ulcer as a result from trauma on a patient with venous insufficiency. The wound measured approximately 1cm² when treatment with Woulgan was initiated.

Week 1 - 17th September 2015

- Woulgan was applied to the wound for the first time and covered with a foam dressing

Week 2-5

- The dressing is changed twice a week and new Woulgan applied
- The patient uses compression stockings throughout the whole treatment period

Week 5 - 20th October 2015

- (Figure 4)
- Complete healing observed

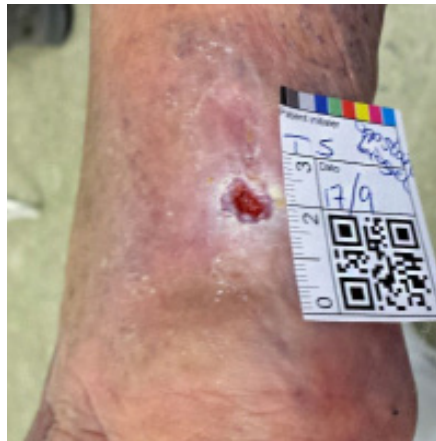

Figure 1: Start of Woulgan treatment

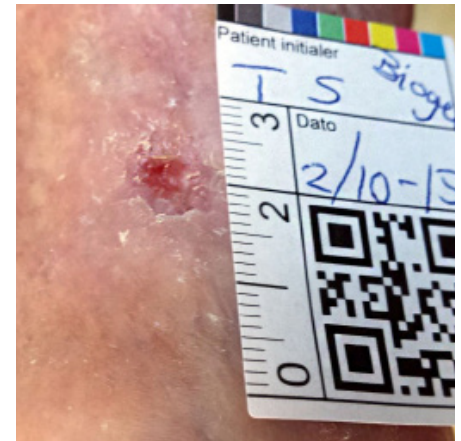

Figure 2: Week 2 of Woulgan treatment

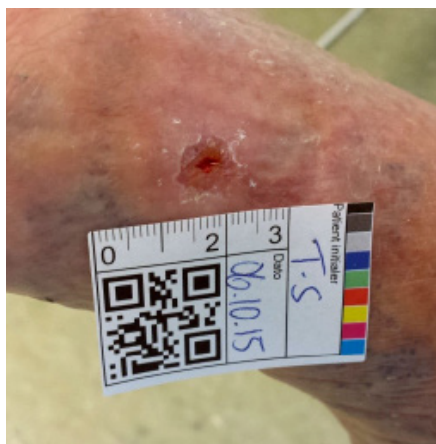

Figure 3: Week 3 of Woulgan treatment

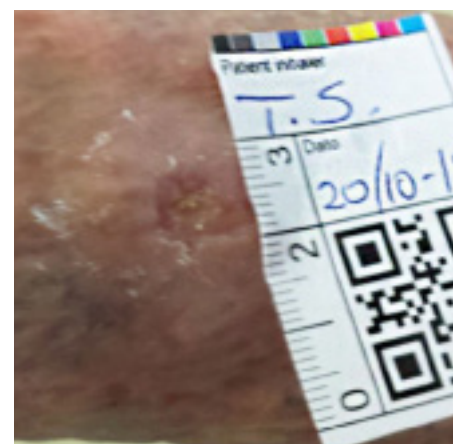


Figure 4: Complete healing after a little over 4 weeks of Woulgan treatment

RESULTS AND DISCUSSION

- Despite wearing compression stockings together with other measurements, the wound was still open after 3,5 months
- Treatment with Woulgan was initiated and the wound healed after only 4 weeks
- The patient experienced the dressing changes and the application of Woulgan as comfortable and painless
- No pain relief treatment or treatment with antibiotics was needed
- The health care professionals claimed Woulgan was easy to use and experienced no safety issues