

Successful use of an immunomodulator, Bioactive β ta-glucans, to progress a diabetic foot open amputation wound to final closure post negative pressure wound therapy: A case study.

Author: Tania Woodrow, Specialist Podiatrist, Cornwall Partnership NHS Foundation Trust

In Diabetes it has been suggested that macrophages become senescent within the wound environment and are dysfunctional in the production of the neurotransmitters and growth factors essential for the co-ordination of wound healing. Skjæveland and Engstad¹, indicate that such macrophages are receptive to stimulation by β ta-glucans, which result in the restoration of the wound healing process via the production of growth factors and cell signalling molecules.

Diabetic foot wounds are notoriously difficult and slow to heal. Bioactive β ta-glucans are available for use in open post-operative wounds where wound healing is anticipated to be slow. Within our surgical teams Negative Pressure Wound Therapy, (NPWT), is requested post foot amputation to optimise granulation tissue formation, increase local perfusion and provide a closed wound environment. It is our experience that amputation wounds can be slow to progress to final closure post NPWT.

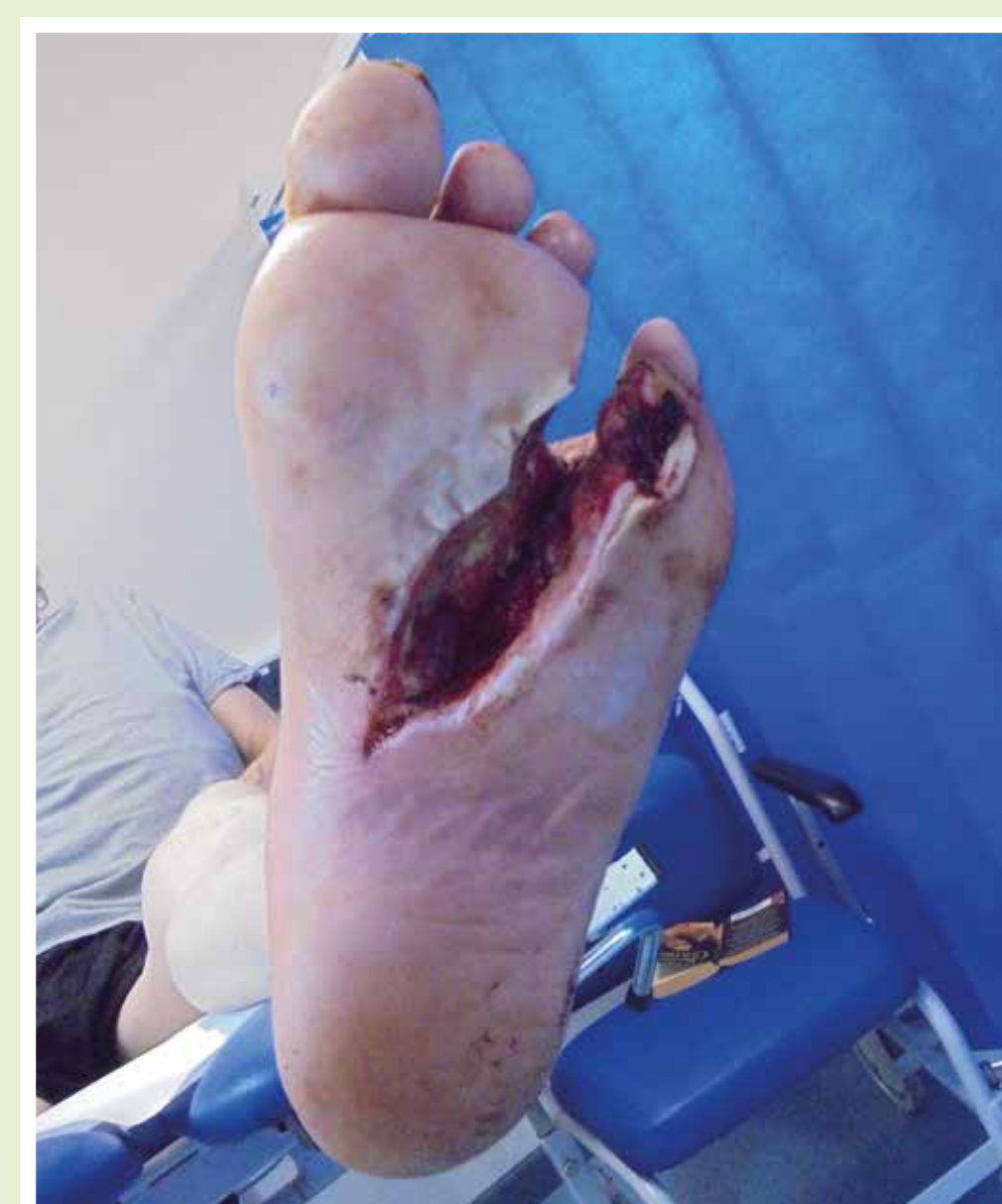This case study reports the first use of Bioactive β ta-glucan gel to move a diabetic amputation wound to final closure post NPWT.

Method

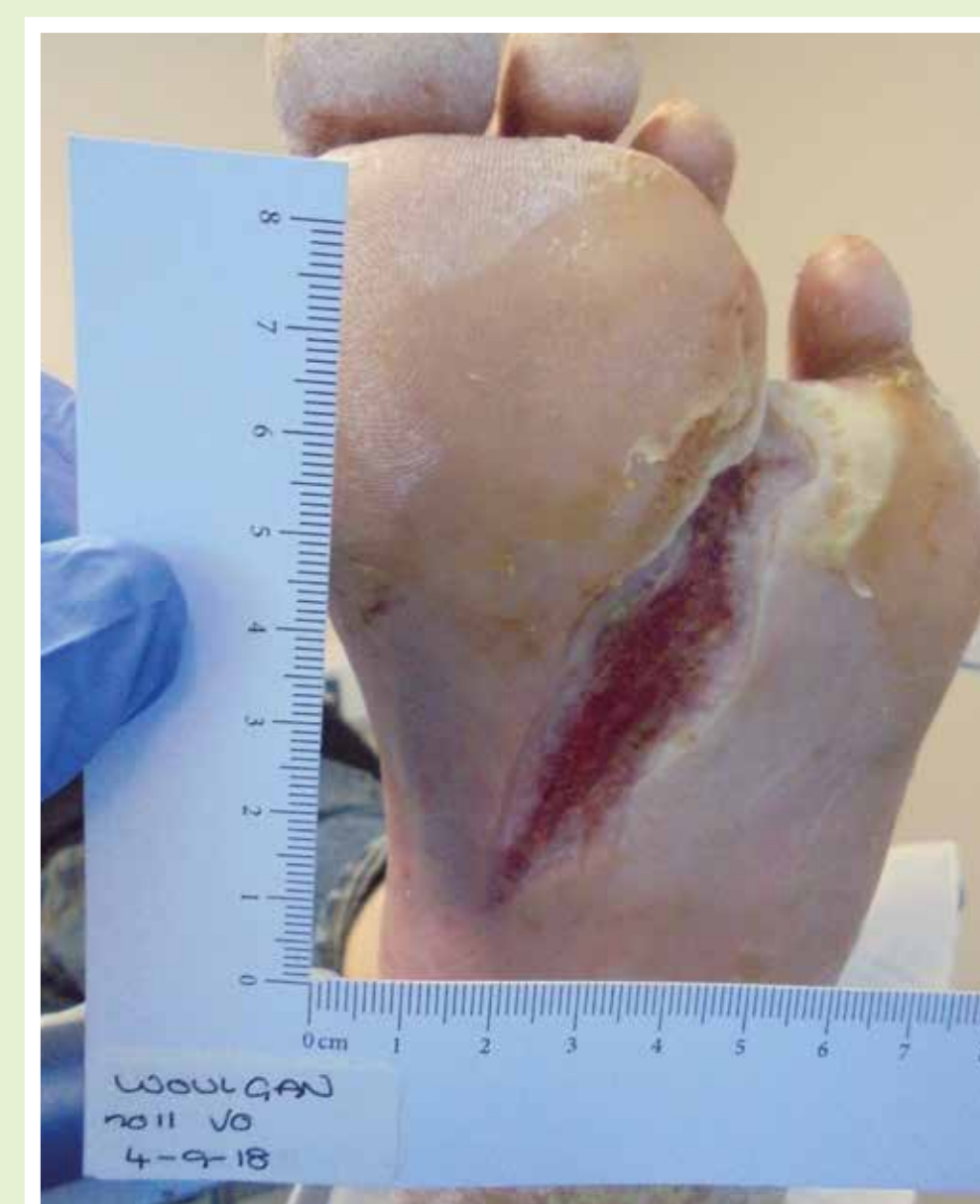A 67 year old diabetic male, with good Diabetes control, peripheral neuropathy and altered foot architecture, presented with a forefoot abscess requiring 4th ray amputation and debridement of plantar tissue. Immediately post-surgery NPWT was applied to the amputation site. After five weeks of treatment, the tissue deficit measured 4.7 cm², covered with 100% granulation tissue. At this stage, the Bioactive β ta-glucan gel was applied directly to the granulation tissue and covered by a foam secondary dressing for optimal moist wound healing. The foot wound was offloaded within a modified post-op shoe. The gel was applied weekly and wound area measured with Image-J software to determine % change in wound area.

Results % Wound area reduction: -

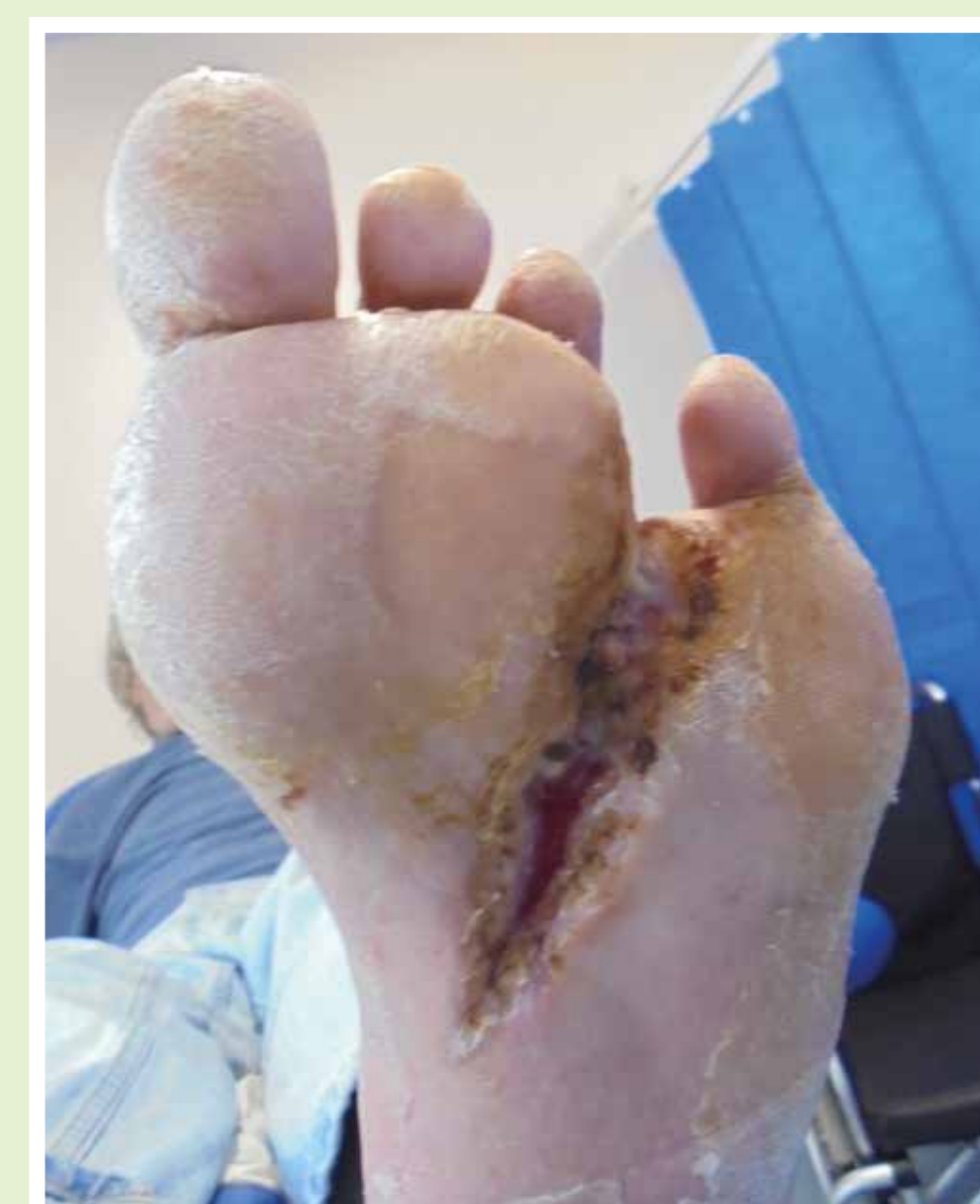Post amputation
(30/07/18)



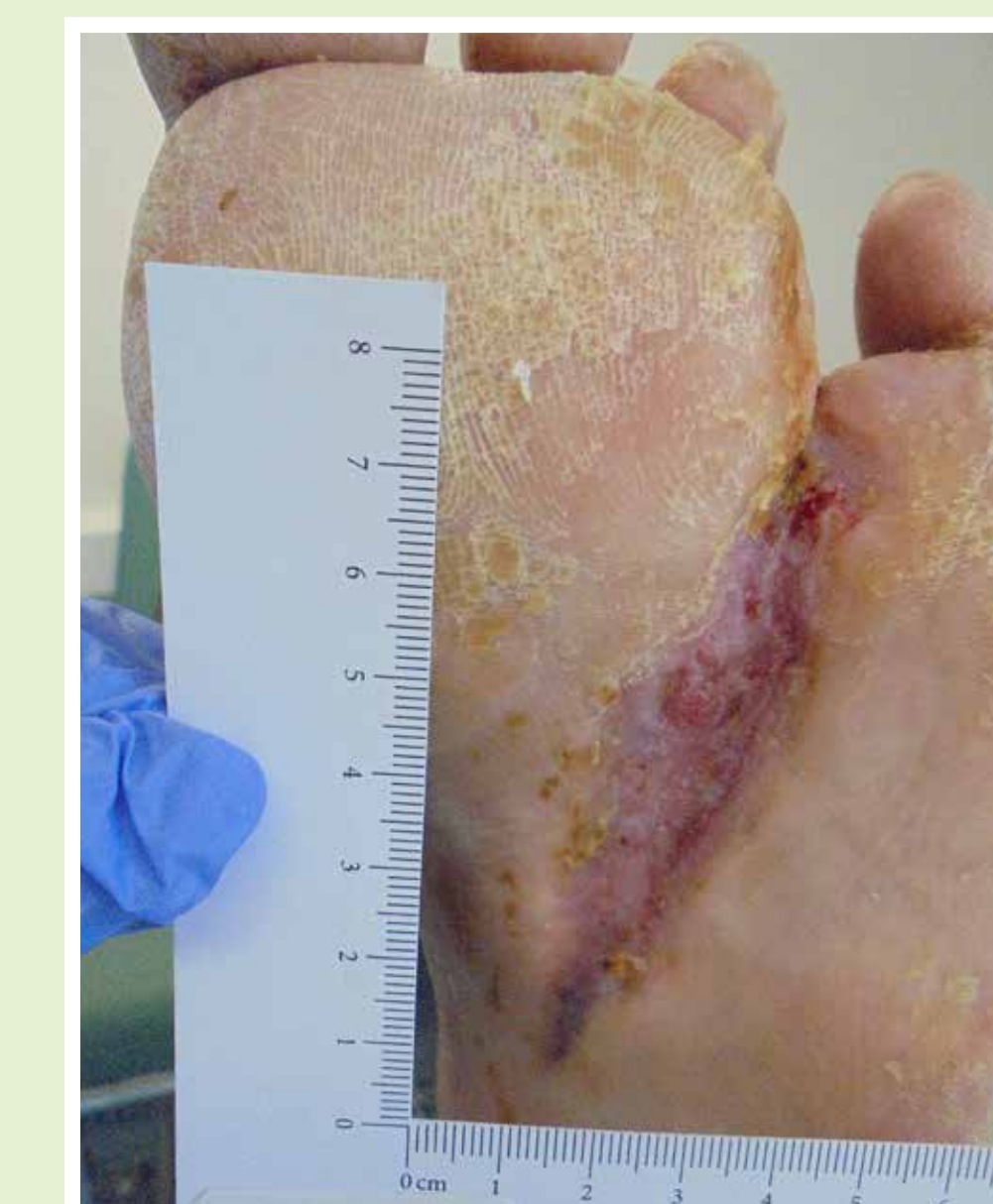Visit 0 Bioactive β ta-glucans started
(04/09/18)



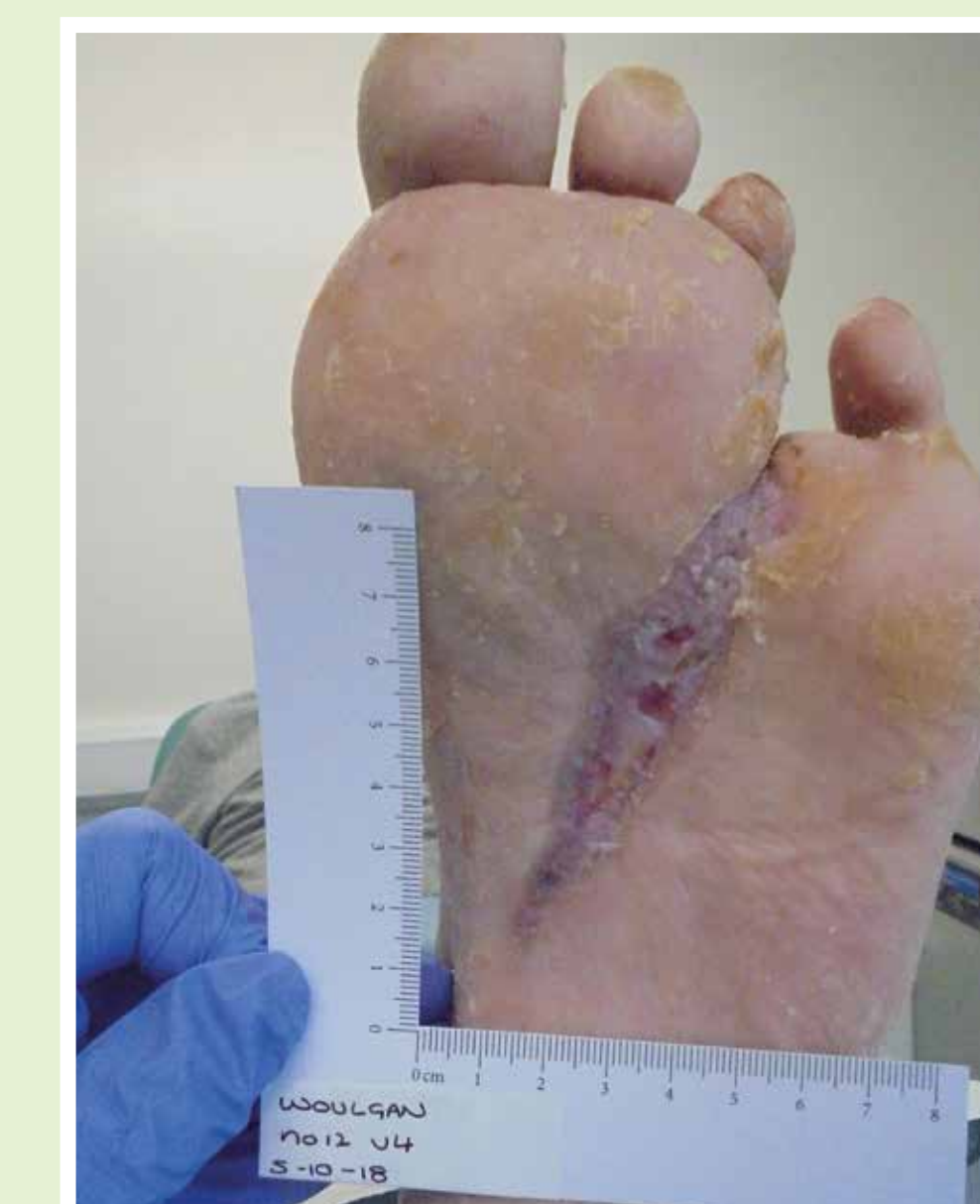Visit 1 68% reduction
(11/09/2018)



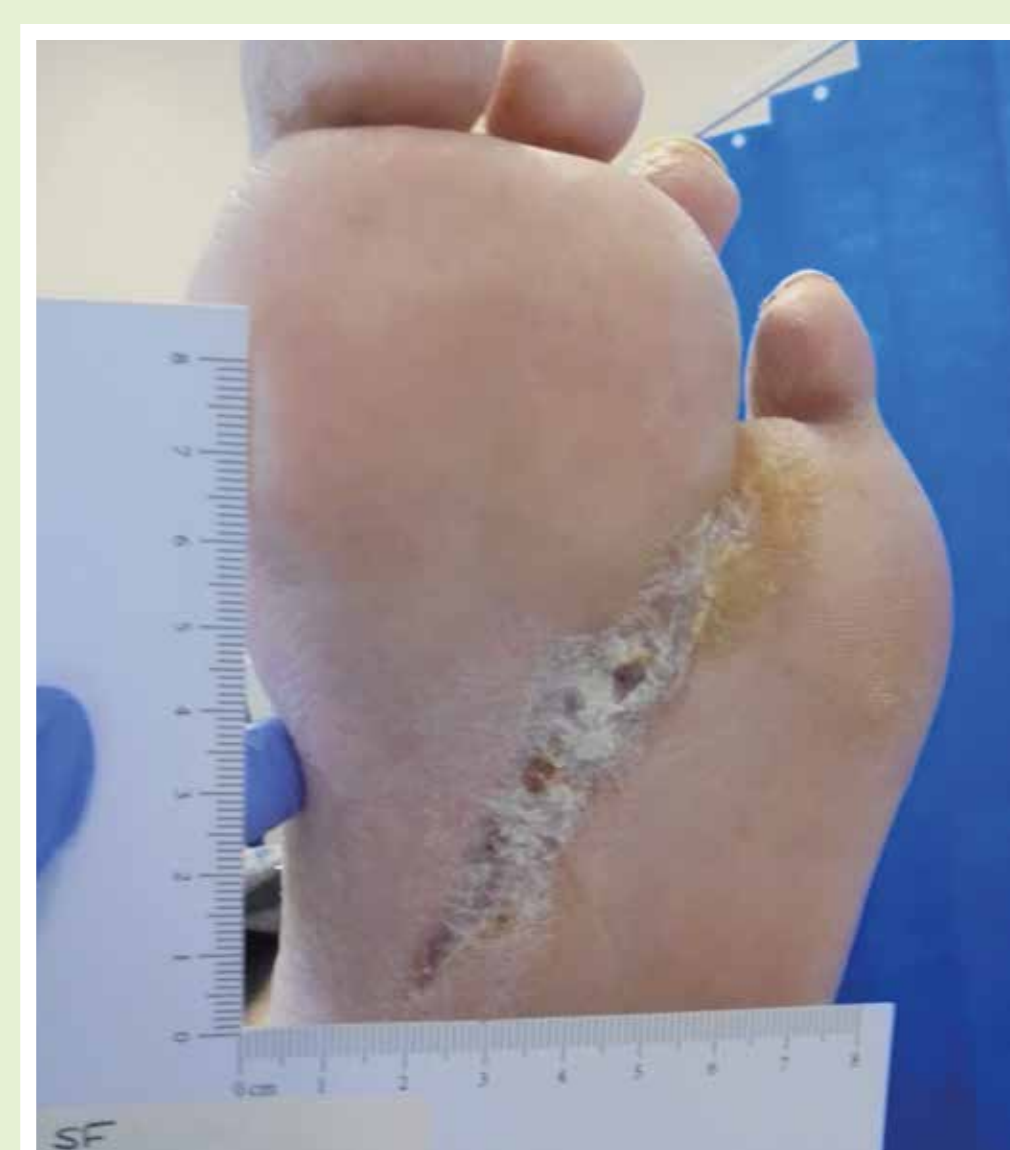Visit 2 81% reduction
(21/09/2018)



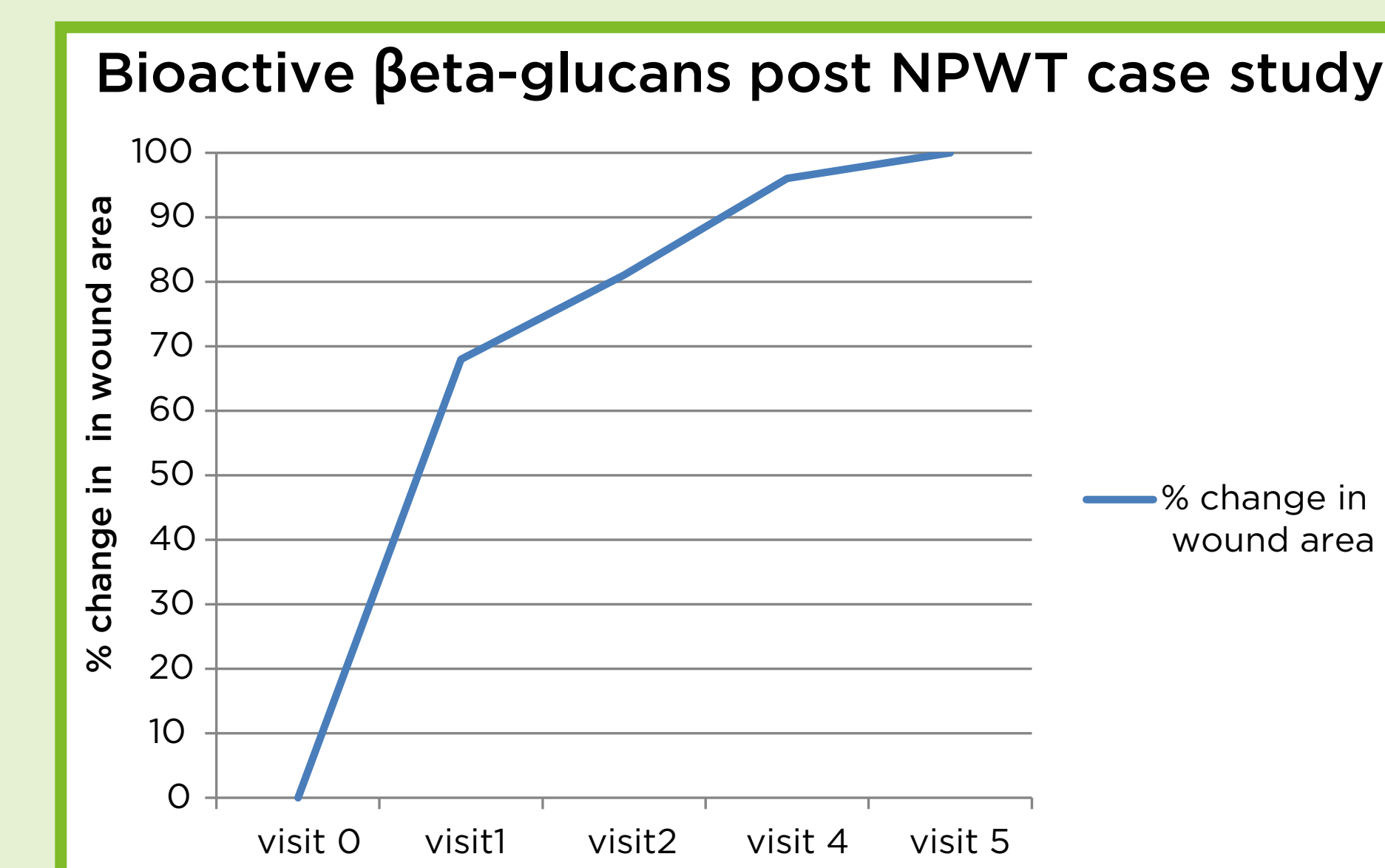
Visit 4 96% reduction
(05/10/2018)



3 months post surgery
(02/11/2018)



The patient failed to attend visit 3 and did not seek alternative wound care, therefore the dressing was in place for 2 weeks. At week 5 the wound was fully epithelialised and at 3 months post-surgery the area remains intact with robust scar tissue.



Graph to depict the trajectory of wound area reduction seen with the use of Bioactive β ta-glucans post NPWT in a diabetic ray amputation wound.

Discussion

In this case study an immunomodulator, in addition to moist wound healing and offloading, progressed a diabetic foot amputation wound to final closure 5 weeks post NPWT. A 2-year audit, undertaken to determine amputation outcomes with in our clinical area (unpublished data), revealed that post NPWT single ray amputation wounds on average took 15.1 weeks to reach final closure post NPWT, (n=13).

Conclusion

This case study has demonstrated an ability to move a diabetic amputation wound to final closure, however, a more robust study would need to be undertaken to determine the effectiveness of Bioactive β ta-glucans in the management of diabetic foot amputation wounds.